

Published in final edited form as:

Alzheimer Dis Assoc Disord. 2013 ; 27(4): . doi:10.1097/WAD.0b013e31828cc357.

Neurodegenerative disease phenotypes in carriers of *MAPT* p.A152T, a risk factor for frontotemporal dementia spectrum disorders and Alzheimer's disease

Suzee E. Lee, MD¹, Maria Carmela Tartaglia, MD², Görsev Yener, MD³, Sermin Genç, MD³, William W. Seeley, MD¹, Pascual Sanchez-Juan, MD PhD⁴, Fermin Moreno, MD⁵, Mario F. Mendez, MD PhD⁶, Eric Klein, MSc⁷, Rosa Rademakers, PhD⁸, Adolfo López de Munain, MD PhD⁵, Onofre Combarros, MD⁴, Joel H. Kramer, PsyD¹, Robert O. Kenet, MD PhD⁹, Adam L. Boxer, MD PhD¹, Michael D. Geschwind, MD, PhD¹, Maria-Luisa Gorno-Tempini, MD PhD¹, Anna M. Karydas¹, Gil D. Rabinovici, MD¹, Giovanni Coppola, MD⁷, Daniel Geschwind, MD PhD⁷, and Bruce L. Miller, MD¹

¹University of California, San Francisco, Memory and Aging Center, Department of Neurology

²University of Toronto, Tanz Centre for Research in Neurodegenerative Disease

³Dokuz Eylül University, Departments of Neurology and Neurosciences, Brain Dynamics Research Center; BEYINMER, Istanbul Kultur University

⁴Neurology Service and Centro de Investigación Biomédica en Red sobre Enfermedades Neurodegenerativas (CIBERNED), 'Marqués de Valdecilla' University Hospital, University of Cantabria, Institute for Formation and Research of the Foundation 'Marqués de Valdecilla' (IFIMAV)

⁵Hospital Universitario Donostia, Department of Neurology, San Sebastian, Spain

⁶University of California, Los Angeles, Neurobehavior Division, Department of Neurology

Corresponding author: Suzee E. Lee, MD, Memory and Aging Center, UCSF Department of Neurology, 675 Nelson Rising Lane, Suite 190, San Francisco, CA 94158, suzelee@memory.ucsf.edu, Phone: (415) 514-3572, Fax: (415) 476-4800.

Authors' financial disclosures: Dr. Lee, Dr. Genç, Dr. Sanchez-Juan, Dr. Moreno, Dr. Tartaglia, Dr. Mendez, Mr. Klein, Dr. López de Munain, Dr. Combarros, Dr. Kramer, Dr. Kenet, Dr. Gorno-Tempini, Dr. Coppola, Dr. Daniel Geschwind, and Ms. Karydas report no disclosures.

Dr. Yener received honoraria from Lundbeck, Novartis, Pfizer, Janssen-Cilag, Zentiva, Sanovel and Abdi Ibrahim companies for lectures.

Dr. Seeley is funded by NIH grants P50 AG1657303, the John Douglas French Alzheimer's Disease Foundation, Consortium for Frontotemporal Dementia Research, James S. McDonnell Foundation, Larry Hillblom Foundation, has received support for travel by the Alzheimer's Association, served as a consultant for Bristol Myers Squibb, and received payment for lectures by the Alzheimer's Association, American Academy of Neurology and Novartis Korea.

Dr. Rademakers received honoraria for lectures or educational activities not funded by industry and serves on the Medical Advisory Board of the Association for Frontotemporal Dementia.

Dr. Boxer has been a consultant for Accera, Bristol Myers Squibb, Genentech, Medivation, Phloronol, Registrat-Mapi and TauRx. He has received research funding from Allon Therapeutics, Avid, Elan, Forest, Genentech, Janssen, Medivation and Pfizer.

Dr. Michael Geschwind has served as a consultant for Medacoro, Clinical Advisors, Gerson Lehman Group and is on the Editorial Board of Dementia Cognition.

Dr. Rabinovici receives research support from Avid Radiopharmaceuticals, has consulted for Eli Lilly and Novartis Diagnostics, and has received honoraria for lectures or educational activities not funded by industry.

Dr. Miller serves as a consultant for TauRx and Allon Therapeutics. He has also received a research grant from Novartis. He has received an honorarium for his work on the Tau Consortium. He is on the Board of Directors for the John Douglas French Foundation for Alzheimer's Research and for The Larry L. Hillblom Foundation.

Publisher's Disclaimer: This is a PDF file of an unedited manuscript that has been accepted for publication. As a service to our customers we are providing this early version of the manuscript. The manuscript will undergo copyediting, typesetting, and review of the resulting proof before it is published in its final citable form. Please note that during the production process errors may be discovered which could affect the content, and all legal disclaimers that apply to the journal pertain.

⁷University of California, Los Angeles, Departments of Psychiatry and Neurology

⁸Mayo Clinic, Department of Neuroscience

⁹Weill Medical College of Cornell University, Department of Medicine

Abstract

Recently, Coppola and colleagues demonstrated that a rare *MAPT* sequence variant, c.454G>A (p.A152T), significantly increases the risk of frontotemporal dementia (FTD) spectrum disorders and Alzheimer's disease (AD) in a screen of 15,369 subjects¹. We describe clinical features of 9 patients with neurodegenerative disease (4 women) harboring p.A152T, aged 51 to 79 years at symptom onset. Seven developed FTD spectrum clinical syndromes, including progressive supranuclear palsy syndrome (PSP, n=2), behavioral variant FTD (bvFTD, n=1), nonfluent variant primary progressive aphasia (nfvPPA, n=2), and corticobasal syndrome (CBS, n=2); two patients were diagnosed with clinical AD. Thus, *MAPT*p.A152T is associated with a variety of FTD spectrum clinical presentations, although patients with clinical AD are also identified. These data warrant larger studies with clinicopathological correlation to elucidate the influence of this genetic variant on neurodegenerative disease.

Keywords

All Cognitive Disorders/Dementia; Alzheimer's disease; Frontotemporal Dementia; Corticobasal degeneration; Progressive Supranuclear Palsy

Introduction

Microtubule associated protein tau (*MAPT*) mutations often occur in the microtubule-binding domain; *MAPT* mutations may lead to alterations in microtubule dynamics or increase 4R tau production.² c.454G>A (p.A152T) is a rare sequence variant in exon 7 of *MAPT* on chromosome 17, occurring at a heterozygote frequency of approximately 0.41%.¹ Functional assays reveal that p.A152T decreases the binding of tau to microtubules, resulting in less efficient microtubule assembly.¹ Also, p.A152T is associated with increases in tau oligomer formation.¹ Recently, Coppola and colleagues reported in 15,369 subjects that p.A152T significantly increases the risk for FTD-spectrum disorders (n= 2,139, OR = 3.0, CI: 1.6-5.6, p=0.0005) and AD (n= 3,345, OR = 2.3, CI: 1.3-4.2, p=0.004) compared to 9,047 controls.¹

Several patients with neurodegenerative disease carrying *MAPT*p.A152T have been described. A 67 year-old man with progressive cognitive decline over five years starting with memory impairment followed by a speech disorder and frontal lobe symptoms showed left-sided myoclonus and stereotypies in late stages of disease.³ Autopsy revealed an atypical 4R tauopathy. Another report described patients with parkinsonism and neurofibrillary tangle pathology (n=2), corticobasal degeneration (n=1), and Parkinson's disease (n=1).⁴

Here we describe nine patients with neurodegenerative disease who harbor *MAPT*p.A152T, all of whom come from the large screen performed in our previous study.¹ Seven of nine presented with FTD-spectrum clinical syndromes associated with FTLT-tau, whose predominant clinical syndromes were PSP (2), bvFTD (1), nfvPPA (2), and CBS (2). Two patients received clinical diagnoses of Alzheimer's disease.

Methods

Patients with neurodegenerative disease (n=10,310) and healthy controls (n=5059) were screened for *MAPT* p.A152T in the parent study (Coppola 2012). We screened an additional 765 patients with neurodegenerative disease and 427 healthy controls from the University of Cantabria and Hospital Universitario Donostia, and 40 patients with dementia and 41 healthy controls from Dokuz Eylül University. This series includes patients with neurodegenerative disease from this genetic screen for which detailed clinical information was available retrospectively. Four clinical evaluations occurred at the University of California, San Francisco Memory and Aging Center (UCSF MAC), one at University of California, Los Angeles (UCLA) Neurobehavior Clinic, one at Hospital Universitario Donostia, San Sebastian, Spain, and two at the dementia outpatient clinic of Dokuz Eylül University, Izmir, Turkey. Evaluations included a history and physical examination by a behavioral neurologist. Neuropsychological data, including tests of global cognition (Mini Mental State Exam, MMSE), verbal learning (California Verbal Learning and Consortium to Establish a Registry for Alzheimer's Disease (CERAD) Verbal Learning), fluency, naming (Abbreviated Boston Naming Test), visuospatial construction (Benson figure), calculations and executive function (Modified Trails) are reported where available.^{5, 6} Functional status was measured using the Clinical Dementia Rating (CDR) scale,⁷ and behavioral symptoms were measured using the Neuropsychiatric Inventory (NPI).⁸ Brain MRI, CT or positron emission tomography (PET) with fluorodeoxyglucose (FDG) or Pittsburgh Compound-B (PIB) were performed in a subset of patients (see Supplementary Materials for details).

Genetic testing for mutations causing FTD (*MAPT*, *GRN*, and *C9ORF72*),^{9, 10}, apolipoprotein (*APOE*), and the extended *MAPT* haplotype, which is overrepresented in CBD and PSP,¹¹ was performed in all patients and controls.¹ (See Supplementary Materials.)

The research protocol was approved by the UCSF, UCLA, Hospital Universitario Donostia, and Dokuz Eylül University institutional review boards for human research. All participants or their surrogates consented to the research protocols. Details regarding age, sex, and occupation have been altered for some cases to obscure patient identities.

Results

Patient 1

A 51 year old woman had diplopia, difficulty with peripheral vision, and apathy three years before evaluation. A year later, fine hand movements, such as fastening buttons, proved challenging and she noted short term memory changes and word-finding difficulty. Two years from symptom onset, she had frequent falls, dropped objects and had trouble controlling her car steering wheel. Dysarthria and dysphagia emerged, and her family noted that she laughed and cried uncontrollably. One brother had epilepsy and another brother was diagnosed with OCD and schizophrenia. Four other siblings were healthy.

Exam revealed masked facies, the procerus sign (vertical wrinkling of the forehead)¹² and pseudobulbar affect. Speech was dysarthric and she was bradykinetic. Saccadic eye movements had increased latency and reduced velocity, more prominently in the vertical than horizontal plane. Exam showed marked axial rigidity and bilateral limb rigidity more prominent on the left with left arm dystonia. Deep tendon reflexes were brisk throughout, more on the left, and plantar responses were flexor. Cerebellar signs were absent; sensory exam was normal. Gait was wide based and stooped and she exhibited moderate retropulsive instability. While she carried a PSP clinical diagnosis, she did not meet research criteria for PSP because falls did not begin within 2 years of symptom onset.¹³

Neuropsychological testing revealed mild global cognitive impairments. Brain MRI showed mild dorsomedial frontal and midbrain atrophy (Figure 1).

Patient 2

A 62 year-old woman had falls, slurred speech, a right arm tremor and personality changes two years before evaluation. One year before evaluation, she developed a shuffling gait and had difficulty seeing tennis balls on the ground.

Once highly charismatic, she grew quiet and passive. She became impatient and agitated, displaying disinhibition in social situations. She was extremely anxious about terrorist attacks and worried about her personal safety. Her lifelong difficulty with overeating intensified several years before evaluation. Cognitive symptoms included subtle changes in planning and multitasking. Memory remained intact. Subsequently, she noticed difficulty looking downward, and she developed urinary frequency. She cried easily, although she denied feeling depressed. Her mother, 5 maternal aunts and uncle had a history of psychiatric neurodegenerative illness, some requiring institutionalization in late life.

On examination, speech was mildly dysarthric and aprosodic. Apraxia was absent. Facies was masked. The procerus sign and square wave jerks were present. Vertical saccade velocity was reduced with downgaze slower than upgaze. There was mild axial rigidity and asymmetric upper extremity cogwheel rigidity, more prominent on the left. Mild, symmetric hypertonia was present in the lower extremities. Tremor and dysmetria were absent. Repetitive hand and foot movements and sensory exam were normal. Deep tendon reflexes were 2+ and plantar responses were flexor. Her gait had diminished left arm swing and mild retropulsive instability.

Over the next two years, she had absent downgaze and slowed horizontal saccade velocities. Axial and appendicular rigidity worsened. Gait grew more bradykinetic with shuffling, and she held her left arm flexed at her side. The predominant clinical diagnosis was PSP with elements of bvFTD.

Neuropsychological testing showed impairments in episodic and working memory, processing speed, and executive function. Subsequent evaluations revealed declines in affected domains with new impairments in visuospatial construction and memory.

CSF A β and tau tests were inconclusive for AD (Table 1). Brain MRI showed no atrophy or structural lesions on visual inspection (Figure 1).

Patient 3

A 69 year-old man had personality changes starting a year and a half before presentation. Previously outgoing, he rarely initiated conversations, and his responses grew terse. He gained 20 pounds in one year due to less exercise and a new preference for desserts. He persisted in activities, such as eating, unless prompted to stop. He rubbed his thigh with his hand and locked doors repetitively. Memory and language functions were normal. A maternal aunt and uncle were thought to have AD. One child was diagnosed with depression.

On examination, he had mildly masked facies and a paucity of spontaneous speech. He had trouble demonstrating a wave goodbye. Cranial nerve examination was unremarkable. Mild axial rigidity was present; appendicular tone was normal. Power in the limbs was full, and tremor was absent. No dysmetria was noted. Deep tendon reflexes were slightly brisker on the left; ankle jerks were absent and plantar responses were flexor. Proprioception and vibration sensitivity were diminished in the feet. Gait showed slightly diminished left arm

swing. He had no retropulsive instability. One year later, verbal output diminished further and he had developed a bilateral low amplitude, high frequency postural tremor. He met criteria for bvFTD¹⁴, eventually developing a few motor features.

Neuropsychological tests showed below average verbal and visual fluency, working memory, and set-shifting. Verbal and visual memory, figure copying, and calculations were within normal limits for age. The following year, he showed significant declines across all cognitive domains, except figure copying, which remained normal.

Brain MRI showed severe bilateral frontal atrophy, more prominent on the left, with relative sparing of temporal cortex. He died 7 years after his initial symptoms.

Patient 4

A 69 year-old woman presented with language and speech difficulties. She had problems with naming, and speech was stuttering, hesitant and effortful. Comprehension, memory, orientation and other cognitive domains were spared. Five years after her first symptoms, she became mute. At this time, she developed anxiety and aggression. Other behavioral symptoms such as apathy, disinhibition, hyperorality and psychosis were absent. Her brother was diagnosed with ALS and died two years later at the age of 36.

Two years after symptom onset, neurological examination showed no abnormalities with no signs of parkinsonism or motor neuron disease. Clinical diagnosis was nfvPPA.¹⁵

Brain MRI showed bilateral insular atrophy, slightly more prominent on the left. Seven years after symptom onset, she developed dysphagia and died from choking on food.

Patient 5

A 56 year-old man presented with word-finding difficulties; a year later, he developed significant difficulty speaking for days after an orthopedic surgery under general anesthesia. A brain MRI was unrevealing. His language recovered somewhat over days, but subsequently worsened over several years.

He also developed insidious personality changes. Previously outgoing, he grew withdrawn and anxious. He cried easily in response to mild emotional triggers, such as sentimental commercials. He played computer card games repetitively. A paternal uncle and maternal grandmother developed parkinsonism in their fifties. His brother stuttered beginning in childhood. On his paternal side, there was a history of alcohol use and suicide.

At presentation, 3 years after symptom onset, examination revealed mild disinhibition, impulsivity and exaggerated playfulness. Apraxia was absent. Language was agrammatic with apraxia of speech and phonemic paraphasias. He followed simple commands and could only repeat single words. Cranial nerve examination was normal. There was mild right upper extremity hypertonia with augmentation and no axial rigidity. Rapid hand movements were slow on the left. There was a mild high-frequency, low-amplitude postural left arm tremor. Deep tendon reflexes were 2+; plantar responses were flexor. Sensation was intact. His hands assumed a mildly flexed posture during ambulation.

Five years after symptom onset, he developed mild memory loss and trouble with problem-solving. Six years after symptom onset, exam showed mild masked facies, a procerus sign, square wave jerks, and slowed velocity and increased latency of vertical saccades. Posture became rigid with diminished arm swing bilaterally but no retropulsive instability. Clinically, he met criteria for nfvPPA¹⁵ with behavioral changes and elements suggestive of PSP syndrome.¹³

Neuropsychological tests revealed word comprehension and repetition deficits, and phonemic paraphasias. Naming was within normal range. Working memory and verbal fluency were below average for his age.

Brain MRI showed bilateral frontal and insular atrophy, worse on the left (Figure 1). Temporal lobe atrophy was worst in the temporal poles and on the left. Parietal lobes were relatively spared. FDG-PET scan showed decreased metabolism in frontotemporal and parietal cortex. PIB-PET scan showed no evidence of amyloid deposition.

Patient 6

A 67 year-old man first noted difficulties with memory, problem solving, and reading three years before evaluation. One year later, his left foot dragged when he walked. Manual dexterity was impaired, particularly on the left. He developed prominent limb myoclonus, greater on the left. Over the next 3 years, depression and apathy worsened and memory and problem solving declined. He became unable to locate objects in his left visual field. His father died in his late 80's with an uncharacterized dementia.

Examination revealed bilateral ideomotor apraxia more prominent on the left. Saccadic eye movements had increased latency to initiation with normal velocity. There was decreased muscle bulk in the left lower extremity, but strength was full. Prominent myoclonus was noted in all extremities, particularly in the left upper extremity. Deep tendon reflexes were symmetrical, with Babinski sign present on the left and absent on the right. On subsequent examinations, he developed prominent left-sided visual neglect, hypomimia, parkinsonism more prominent on the left, and a high frequency, low amplitude postural tremor in the left upper extremity, which assumed dystonic postures. He met criteria for CBS.¹⁶

Neuropsychological testing revealed prominent difficulty with visuospatial construction and mild deficits in visual memory retrieval. Language, verbal memory, and attention were relative strengths. Subsequently, deficits in executive function emerged.

Brain MRI showed mild generalized atrophy with focal anterior greater than posterior insular atrophy and biparietal atrophy, slightly worse on the right and minimal periventricular white matter changes (Figure 1). FDG-PET showed asymmetric right parieto-occipital hypometabolism.

Patient 7

A 68-year-old man presented with intermittent left eyelid flickering and diplopia seven years before evaluation. One year later, word-finding and comprehension difficulties emerged, and he misspelled words. Five years before evaluation, his ability to organize and plan declined. A few years before evaluation, memory declined, articulation and stuttering emerged, and he noted trouble with left leg coordination and using utensils. He made repetitive right hand movements, of which he was unaware. Swallowing grew difficult. He exhibited personality changes including apathy and social withdrawal. His brother, who suffered multiple concussions, had dementia.

On examination, he had masked facies. Speech was hypophonic, effortful, and agrammatic, with numerous paraphasias. Ideomotor apraxia was present in both upper limbs and the left lower extremity. Smooth pursuit eye movements were interrupted. Saccades showed increased latency, reduced velocity, and decreased amplitude in all directions. He had a decreased left nasolabial fold, with symmetric activation of facial muscles. Axial rigidity and mild bilateral arm rigidity were present. The left arm assumed a dystonic posture. There was mild left-sided weakness and hyperreflexia. Plantar responses were flexor bilaterally. Hand grasp reflexes were present bilaterally. Sensory exam was limited, but no neglect was

noted. Gait was bradykinetic with a slightly widened base, normal stride, decreased arm swing bilaterally and posturing of the left arm. Mild postural instability was present.

One year later, he started to mumble and stutter. He developed orobuccal apraxia. Both arms assumed postures when he walked. His left arm drifted and his left hand grabbed his right hand. Clinically, he met criteria for CBS¹⁶ and also exhibited features of nvPPA. Neuropsychological testing revealed a Mini-Mental State Exam (MMSE) score of 7/30.

Brain MRI showed bilateral temporoparietal atrophy worse on the right, bilateral hippocampus atrophy worse on the right, and mild periventricular white matter disease (Figure 1). Brain PET showed bilateral temporoparietal hypometabolism, worse on the right; PIB-PET was positive for beta-amyloid. On account of prominent temporoparietal atrophy and hypometabolism, a positive PIB-PET scan, and CSF studies suggestive of AD, underlying AD pathology was suspected, although co-morbid FTLN-spectrum pathology could not be excluded.

Patient 8

A 79 year-old man had difficulty managing his finances and medications and four years of progressive memory decline. He became suspicious and repeatedly counted his cash, but he remained dynamic and humorous. Language remained intact, but he spoke less. Family history with respect to neurodegenerative disease is limited since his mother died in childbirth at age 30 and his father died at age 45 of unknown cause.

On examination, he was pleasant and cooperative. Cranial nerves were intact. The left upper extremity had mild cogwheel rigidity with augmentation and a mild postural tremor. There was a slight tremor in his right hand when he wrote; dysmetria was absent. Repetitive finger, hand and foot movements were normal. Deep tendon reflexes were 2+ and plantar responses were flexor. Sensory and gait exams were normal. Evaluations over the next couple of years showed no significant changes. He met criteria for probable Alzheimer's disease.¹⁷

MMSE was 20/30 with deficits in short-term memory, working memory, and visuospatial construction. Verbal fluency was impaired. Brain MRI showed generalized atrophy with focal bilateral posterior parietal and hippocampus atrophy and mild posterior periventricular white matter disease (Figure 1).

Patient 9

An 84 year-old woman had progressive memory decline over 5 years. Her initial symptoms included misplacing objects and repeating herself. She was motivated to perform household chores but grew unable to do so. There was no history of behavioral or personality changes, language or speech difficulties, or spatial disorientation. She had a mild, bilateral hand tremor. She had one paternal aunt with dementia.

On examination, she was pleasant and cooperative. Apraxia was absent. Cranial nerves were intact. Strength was full. A mild, high-frequency bilateral postural hand tremor was present. Deep tendon reflexes were symmetrical, ankle jerks were absent, and plantar responses were flexor. Proprioception and vibration sensation were diminished in the feet. Gait was normal and she had no postural instability. She met criteria for probable Alzheimer's disease.¹⁷

Neuropsychological tests showed global deficits; verbal memory and verbal fluency were most affected. Brain MRI showed generalized atrophy with severe medial temporal atrophy (Figure 1).

No patients harbored *MAPT*, *GRN* or *C9ORF72* mutations. Demographic characteristics and genetic testing results are shown in Table 1. Neuropsychological test results are presented in Table 2.

Discussion

Here, we report nine patients with *MAPT*p.A152T. Seven developed an FTD spectrum clinical syndrome starting between ages 51 to 69, whose predominant clinical syndromes include PSP (2), bvFTD (1), nfvPPA (2), and CBS (2). Although these clinical syndromes are each associated with several underlying histopathologies, clinicopathological series have demonstrated that all four syndromes have strong links to underlying tau pathology.¹⁸⁻²³ Two patients with symptom onset in their seventies developed clinical AD. Of note, all patients had a family history of neurodegenerative disease except Patient 7 (whose brother had dementia presumably from multiple concussions) and Patient 8 (whose parents died at ages 30 and 45). Interestingly, Patient 4 had a brother with ALS, which is not associated with FTLT-tau, so the significance of this is unclear.

These observations raise several possible roles for p.A152T in neurodegenerative disease. First, p.A152T may predispose carriers to FTLT-tau spectrum disorders with no influence on AD pathology. Seven of nine patients described here had syndromes strongly linked with FTLT-tau: nfvPPA, CBS, and PSP syndrome.^{16, 18, 22, 24, 25} Non-tau FTLT pathologies can be seen with nfvPPA and CBS;^{16, 26} therefore, clinicopathological correlation is needed to determine whether p.A152T serves as a risk factor for FTLT-tau or for FTLT more broadly.

Another possibility is that p.A152T increases the general risk for neurodegenerative disease. Patients 8 and 9 had clinical AD, and Patient 7 presented with CBS but had evidence of underlying AD pathology, including a positive PIB-PET scan, a CSF profile consistent with AD, and temporoparietal atrophy on MRI, a marker for AD pathology even in atypical presentations.^{16, 27-29} Patient 7 was the only patient who possessed an *APOE* 4 allele, which may explain his early age-of-onset of amyloid deposition, whether or not it represented the primary pathology. While strong indicators suggest that Patient 7 may have underlying AD pathology, mixed FTLT and AD neuropathology remains a strong possibility. Again, autopsy series are needed.

To our knowledge, only one other *MAPT* codon outside the tau microtubule-binding domain has been reported in association with two patients with neurodegenerative disease. Hayashi and colleagues reported a 75 year-old man presenting with memory changes, disorientation, and with p.R5H on *MAPT* occurring in exon 1 at the amino terminus far from the tau microtubule-binding domain.³⁰ Autopsy revealed tau pathology similar to both familial multiple system tauopathy with presenile dementia and PSP. *In vitro*, p.R5H impaired microtubule assembly and promoted fibril formation. Poorkaj and colleagues also reported a patient with a genetic variant at the same codon on *MAPT*, p.R5L, with PSP syndrome, subsequently confirmed as PSP at autopsy.³¹ The authors described delayed microtubule assembly initiation and a lower mass of microtubules formed, noting that epitope studies suggested an interaction between the microtubule binding domain and the amino terminus in paired helical filament tau, but not normal tau, thereby explaining a possible pathogenic mechanism for a genetic variant at this locus.³²

We describe the largest series of detailed clinical information for the *MAPT*p.A152T carriers to date in this report. This series, however, is based on retrospective data and neuropsychological data were unavailable for a subset of subjects. Future prospective studies of *MAPT*p.A152T carriers with neuroimaging and neuropathology are needed to further define *MAPT*p.A152T's clinical correlates.

Future genetic and pathological studies are needed to determine the pathogenic mechanism of p.A152T and explore its potential role in the development of FTL and AD. Studies that screen the entire *MAPT* gene will prove crucial to identifying the full spectrum of tau-related disorders.

Supplementary Material

Refer to Web version on PubMed Central for supplementary material.

Acknowledgments

We would like to thank Dr. William Jagust for PET scans.

Study funding: This work was funded by the Tau Consortium (SEL, GC, DHG, ROK, ALB). SL: K23AG039414-01A1. MFM: R01AG034499-02. GC, DHG: R01 AG026938. GY and SC: the Scientific and Technological Research Council of Turkey (104S255). RR: NIH (R01 NS065782, R01AG02651 and P50 AG16574), the ALS association, CurePSP and the Consortium for Frontotemporal Dementia Research. JHK: 2R01AG022983. ALB: R01AG038791, R01AG031278, the Alzheimer's Drug Discovery Foundation, CurePSP, the Hellman Family Foundation. MDG: 5R01AG031189-2 and the Michael J. Homer Family Fund. MGT: R01NS050915. GDR: K23-AG031861, John Douglas French Alzheimer's Foundation. BLM: AG19724, AG023501, Alzheimers Research Center of California 01-154-20. UL1 RR024131-06.

References

- Coppola G, Chinnathambi S, Lee JJ, et al. Evidence for a role of the rare p.A152T variant in MAPT in increasing the risk for FTD-spectrum and Alzheimer's diseases. *Hum Mol Genet.* May 16.2012
- AD&FTDMDB. <http://www.molgen.ua.ac.be/FTDMutations>
- Kovacs GG, Wohrer A, Strobel T, Botond G, Attems J, Budka H. Unclassifiable tauopathy associated with an A152T variation in MAPT exon 7. *Clin Neuropathol.* Jan-Feb;2011 30(1):3–10. [PubMed: 21176711]
- Kara E, Ling H, Pittman AM, et al. The MAPT p.A152T variant is a risk factor associated with tauopathies with atypical clinical and neuropathological features. *Neurobiol Aging.* May 15.2012
- Kramer JH, Jurik J, Sha SJ, et al. Distinctive neuropsychological patterns in frontotemporal dementia, semantic dementia, and Alzheimer disease. *Cogn Behav Neurol.* Dec; 2003 16(4):211–218. [PubMed: 14665820]
- Dierckx E, Engelborghs S, De Raedt R, et al. The 10-word learning task in the differential diagnosis of early Alzheimer's disease and elderly depression: A cross-sectional pilot study. *Aging Ment Health.* Jan; 2010 15(1):113–121. [PubMed: 20924811]
- Morris JC. The Clinical Dementia Rating (CDR): current version and scoring rules. *Neurology.* Nov; 1993 43(11):2412–2414. [PubMed: 8232972]
- Cummings JL, Mega M, Gray K, Rosenberg-Thompson S, Carusi DA, Gornbein J. The Neuropsychiatric Inventory: comprehensive assessment of psychopathology in dementia. *Neurology.* Dec; 1994 44(12):2308–2314. [PubMed: 7991117]
- Renton AE, Majounie E, Waite A, et al. A hexanucleotide repeat expansion in C9ORF72 is the cause of chromosome 9p21-linked ALS-FTD. *Neuron.* Oct 20; 72(2):257–268. [PubMed: 21944779]
- DeJesus-Hernandez M, Mackenzie IR, Boeve BF, et al. Expanded GGGGCC hexanucleotide repeat in noncoding region of C9ORF72 causes chromosome 9p-linked FTD and ALS. *Neuron.* Oct 20; 72(2):245–256. [PubMed: 21944778]
- Wade-Martins R. Genetics: The MAPT locus—a genetic paradigm in disease susceptibility. *Nat Rev Neurol.* Sep; 2012 8(9):477–478. [PubMed: 22940644]
- Romano S, Colosimo C. Procerus sign in progressive supranuclear palsy. *Neurology.* Nov 27.2001 57(10):1928. [PubMed: 11723296]
- Litvan I, Agid Y, Calne D, et al. Clinical research criteria for the diagnosis of progressive supranuclear palsy (Steele-Richardson-Olszewski syndrome): report of the NINDS-SPSP international workshop. *Neurology.* Jul; 1996 47(1):1–9. [PubMed: 8710059]

14. Neary D, Snowden JS, Gustafson L, et al. Frontotemporal lobar degeneration: a consensus on clinical diagnostic criteria. *Neurology*. Dec; 1998 51(6):1546–1554. [PubMed: 9855500]
15. Gorno-Tempini ML, Hillis AE, Weintraub S, et al. Classification of primary progressive aphasia and its variants. *Neurology*. Mar 15; 2011 76(11):1006–1014. [PubMed: 21325651]
16. Lee SE, Rabinovici GD, Mayo MC, et al. Correlates of Alzheimer's Disease Pathology in Corticobasal Syndrome. *Ann Neurol*. 2011
17. McKhann G, Drachman D, Folstein M, Katzman R, Price D, Stadlan EM. Clinical diagnosis of Alzheimer's disease: report of the NINCDS-ADRDA Work Group under the auspices of Department of Health and Human Services Task Force on Alzheimer's Disease. *Neurology*. Jul; 1984 34(7):939–944. [PubMed: 6610841]
18. Boeve BF, Maraganore DM, Parisi JE, et al. Pathologic heterogeneity in clinically diagnosed corticobasal degeneration. *Neurology*. Sep 11; 1999 53(4):795–800. [PubMed: 10489043]
19. Forman MS, Farmer J, Johnson JK, et al. Frontotemporal dementia: clinicopathological correlations. *Ann Neurol*. Jun; 2006 59(6):952–962. [PubMed: 16718704]
20. Hodges JR, Davies RR, Xuereb JH, et al. Clinicopathological correlates in frontotemporal dementia. *Ann Neurol*. Sep; 2004 56(3):399–406. [PubMed: 15349867]
21. Josephs KA, Duffy JR, Strand EA, et al. Clinicopathological and imaging correlates of progressive aphasia and apraxia of speech. *Brain*. Jun; 2006 129(Pt 6):1385–1398. [PubMed: 16613895]
22. Josephs KA, Petersen RC, Knopman DS, et al. Clinicopathologic analysis of frontotemporal and corticobasal degenerations and PSP. *Neurology*. Jan 10; 2006 66(1):41–48. [PubMed: 16401843]
23. Llado A, Sanchez-Valle R, Rey MJ, et al. Clinicopathological and genetic correlates of frontotemporal lobar degeneration and corticobasal degeneration. *J Neurol*. Apr; 2008 255(4):488–494. [PubMed: 18357425]
24. Josephs KA, Dickson DW. Diagnostic accuracy of progressive supranuclear palsy in the Society for Progressive Supranuclear Palsy brain bank. *Mov Disord*. Sep; 2003 18(9):1018–1026. [PubMed: 14502669]
25. Litvan I, Agid Y, Goetz C, et al. Accuracy of the clinical diagnosis of corticobasal degeneration: a clinicopathologic study. *Neurology*. Jan; 1997 48(1):119–125. [PubMed: 9008506]
26. Rohrer JD, Geser F, Zhou J, et al. TDP-43 subtypes are associated with distinct atrophy patterns in frontotemporal dementia. *Neurology*. Dec 14; 75(24):2204–2211. [PubMed: 21172843]
27. Rabinovici GD, Jagust WJ, Furst AJ, et al. Abeta amyloid and glucose metabolism in three variants of primary progressive aphasia. *Ann Neurol*. Oct; 2008 64(4):388–401. [PubMed: 18991338]
28. Whitwell JL, Jack CR Jr, Przybelski SA, et al. Temporoparietal atrophy: A marker of AD pathology independent of clinical diagnosis. *Neurobiol Aging*. Nov 13.2009
29. Gorno-Tempini ML, Dronkers NF, Rankin KP, et al. Cognition and anatomy in three variants of primary progressive aphasia. *Ann Neurol*. Mar; 2004 55(3):335–346. [PubMed: 14991811]
30. Hayashi S, Toyoshima Y, Hasegawa M, et al. Late-onset frontotemporal dementia with a novel exon 1 (Arg5His) tau gene mutation. *Ann Neurol*. Apr; 2002 51(4):525–530. [PubMed: 11921059]
31. Poorkaj P, Muma NA, Zhukareva V, et al. An R5L tau mutation in a subject with a progressive supranuclear palsy phenotype. *Ann Neurol*. Oct; 2002 52(4):511–516. [PubMed: 12325083]
32. Carmel G, Mager EM, Binder LI, Kuret J. The structural basis of monoclonal antibody Alz50's selectivity for Alzheimer's disease pathology. *J Biol Chem*. Dec 20; 1996 271(51):32789–32795. [PubMed: 8955115]

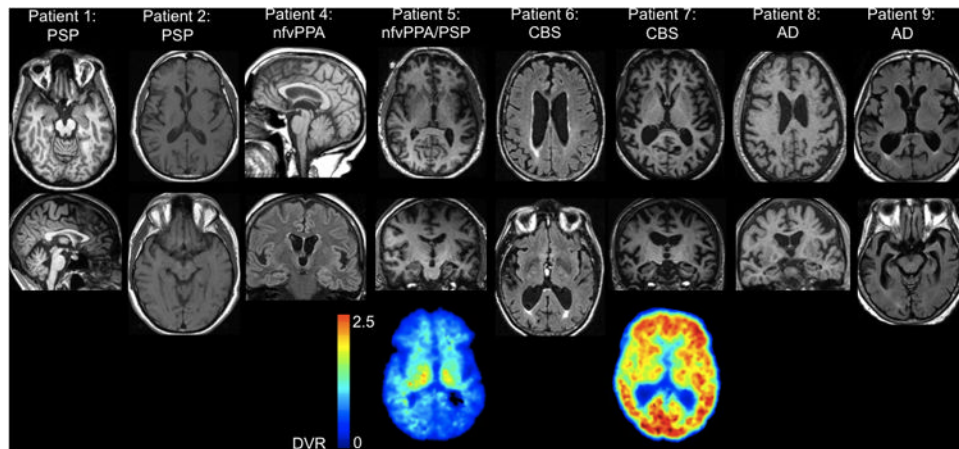


Figure 1.

MRI brain of: Patient 1 with PSP, T1 axial and sagittal show midbrain and dorsomedial frontal atrophy; Patient 2 with PSP, T1 axial shows no atrophy or lesions; Patient 4 with nfvPPA, T1 sagittal and coronal FLAIR reveal mild bilateral insular atrophy, slightly more prominent on the left; Patient 5 with nfvPPA and elements of PSP, T1 axial and coronal reveal bilateral frontal and insular atrophy, worse on the left, temporal atrophy worst in the temporal poles and on the left. PIB-PET is negative for beta-amyloid; Patient 6 with CBS, FLAIR axial shows mild generalized atrophy with focal anterior greater than posterior insular and biparietal atrophy, slightly worse on the right and minimal periventricular white matter changes; Patient 7 with CBS, T1 axial and coronal show bilateral temporoparietal atrophy worse on the right, bilateral hippocampus atrophy worse on the right, PIB-PET is positive for beta-amyloid; Patient 8 with AD, T1 axial and coronal show generalized atrophy with focal bilateral posterior parietal and hippocampus atrophy; and Patient 9 with AD, FLAIR axial shows generalized atrophy with severe medial temporal atrophy. All images shown in radiologic orientation.

Table 1

Patient Characteristics

	Patient 1	Patient 2	Patient 3	Patient 4	Patient 5	Patient 6	Patient 7	Patient 8	Patient 9
Clinical Diagnosis	PSP	PSP, elements of bvFTD	bvFTD	nvPPA	nvPPA, elements of PSP	CBS	CBS, elements of nvPPA	AD	AD
Age at Onset/Sex	48F	60 F	67 M	69 F	53 M	64 M	62 M	75 M	79 F
Clinical Symptoms/Signs at Presentation	<ul style="list-style-type: none"> Diplopia Apathy Memory Word finding Falls Pseudobulbar affect Masked facies reduced vertical saccade velocity and increased latency LUE dystonia L-R parkinsonism 	<ul style="list-style-type: none"> personality changes falls gait change executive symptoms reduced vertical saccade velocity hypomimia dysarthria axial rigidity L-R parkinsonism 	<ul style="list-style-type: none"> Apathy Hyperorality Repetitive movement Hypomimia Axial rigidity Diminished L arm swing BUE tremor 	<ul style="list-style-type: none"> Naming difficulty Stuttering Apraxia of speech Reduced blinking 	<ul style="list-style-type: none"> Word-finding Reading language comprehension disinhibition Apraxia of speech LUE postural tremor Arms dystonic 	<ul style="list-style-type: none"> Memory problem solving apraxia L-R Increased saccade latency Limb myoclonus LUE dystonia and tremor L Babinski 	<ul style="list-style-type: none"> Diplopia visual misperceptions Word finding executive symptoms memory hypomimia apraxia of speech Increased saccade latency Axial/bilateral LUE rigidity LUE dystonia and weakness 	<ul style="list-style-type: none"> Memory Suspicious LUE cogwheel rigidity and postural tremor Right hand tremor when writing 	<ul style="list-style-type: none"> Memory Memory LUE cogwheel rigidity and postural tremor Right hand tremor when writing
Family History	<ul style="list-style-type: none"> Brother: OCD/schizophrenia Brother: epilepsy 	<ul style="list-style-type: none"> Mother, 5 maternal aunts: psychiatric degenerative disease 	<ul style="list-style-type: none"> Maternal aunt and uncle: dementia 	<ul style="list-style-type: none"> Brother: ALS 	<ul style="list-style-type: none"> Brother: stuttering Paternal uncle and maternal grandmother: PD Paternal: alcoholism, psychiatric disease 	<ul style="list-style-type: none"> Father: dementia 	<ul style="list-style-type: none"> Brother: dementia (multiple concussions) Brother died at 45 Brother died at 65 from myocardial infarction. 	<ul style="list-style-type: none"> Mother: died at 30 Father: died at 45 Brother died at 65 from myocardial infarction. 	<ul style="list-style-type: none"> Paternal aunt: dementia
CSF laboratory tests (pg/mL) **	-	<ul style="list-style-type: none"> Abeta42: 383 Total tau: 287 Phospho-tau: 41 ATI: 0.66 Inconclusive for AD 	-	-	-	-	<ul style="list-style-type: none"> Abeta42: 139 Total tau: 887 Phospho-tau: 89 ATI: 0.11 Consistent w/AD 	-	-
Genetic Testing(MAPT/APP/E2/E3)	MAPT H1/H1 Apo E3/E3	MAPT H1/H2 Apo E3/E3	MAPT H1/H1 Apo E2/E3	MAPT H1/H2 Apo E3/E3	MAPT H1/H1 Apo E3/E3	MAPT H1/H1 Apo E3/E3	MAPT H1/H1 Apo E4/E2	MAPT H1/H1 Apo E3/E3	MAPT H1/H1 Apo E3/E3

Abbreviations: AD=Alzheimer's disease. ApoE=apolipoprotein E. ATI=amyloid-tau index. BUE=bilateral upper extremity. bvFTD=behavioral variant frontotemporal dementia. CBS=corticobasal syndrome. CSF= cerebrospinal fluid. DTR=deep tendon reflexes. MAPT=microtubule associated protein tau. L=left. LUE=left upper extremity. LLE=left lower extremity. nfvPPA= nonfluent variant primary progressive aphasia. OCD=obsessive-compulsive disorder. PD=Parkinson's disease. PSP=progressive supranuclear palsy. R=right.

* normal reference ranges are: Phospho-tau < 61 pg/mL, ATI= Abeta42/(240 + 1.18 total tau). ATI < 1 is consistent with AD. ATI > 1 for non-AD.

** All 9 subjects tested negative for MAPT, GRN, and C9ORF72 mutations.

Table 2

Neuropsychological Testing

	Patient 1	Patient 2	Patient 3	Patient 5	Patient 6	Patient 7	Patient 8	Patient 9
Age at Evaluation (years)	51	62	69	56	67	68	78	81
MMSE (max=30)	29	29	23	27	27	7	20	15
CDR sum of boxes	6	3	4	2	3.5	9.5	5	14
Neuropsychiatric Inventory Total Score (max=144)	8	53	13	12	-	0	29	15
Verbal learning	-	38/80 ¹	17/36 ²	34/36 ²	17/30 ³	5/9 ²	-	9/30 ⁴
Verbal learning delayed recall	-	7/16 ¹	5/9 ²	8/9 ²	5/10 ³	0/9 ²	-	0/10 ⁴
Verbal recognition	-	13/16 ¹	8/9 ²	8/9 ²	10/10 ³	3/9 ²	-	-
Category Fluency (words/1 min)	-	14	8	12	15	1	8	0
Phonemic fluency (words/1 min)	-	11	5	6	-	7	-	-
Abbreviated Boston Naming Test (max=15)	-	15	14	14	15	2	-	-
Modified Trails (correct lines/min)	-	25.5 ⁵	10.0 ⁵	26.3 ⁵	8.6 ⁶	-	-	-
Benson Figure Copy (max=17)	-	15	16	17	-	1	-	-
Benson Figure Recall (max=17)	-	8	11	15	-	0	-	-
Calculations (max=5)	-	5	4	5	-	0	-	-
Digits Backward	-	4	3	4	3	0	-	-

Abbreviations: MMSE=Mini Mental State Examination, CDR=Clinical Dementia Rating Scale

¹ California Verbal Learning Test (CVLT) Long Form (16 words)

² CVLT Short Form (9 words)

³ Consortium to Establish a Registry for Alzheimer's Disease (CERAD) Verbal Learning (10 words)

⁴ 10 word-learning list (Dierekx et al. 2011)

⁵ Modified Trails Trail-making Test, Part B

⁶ Trail-making Test, Part B